

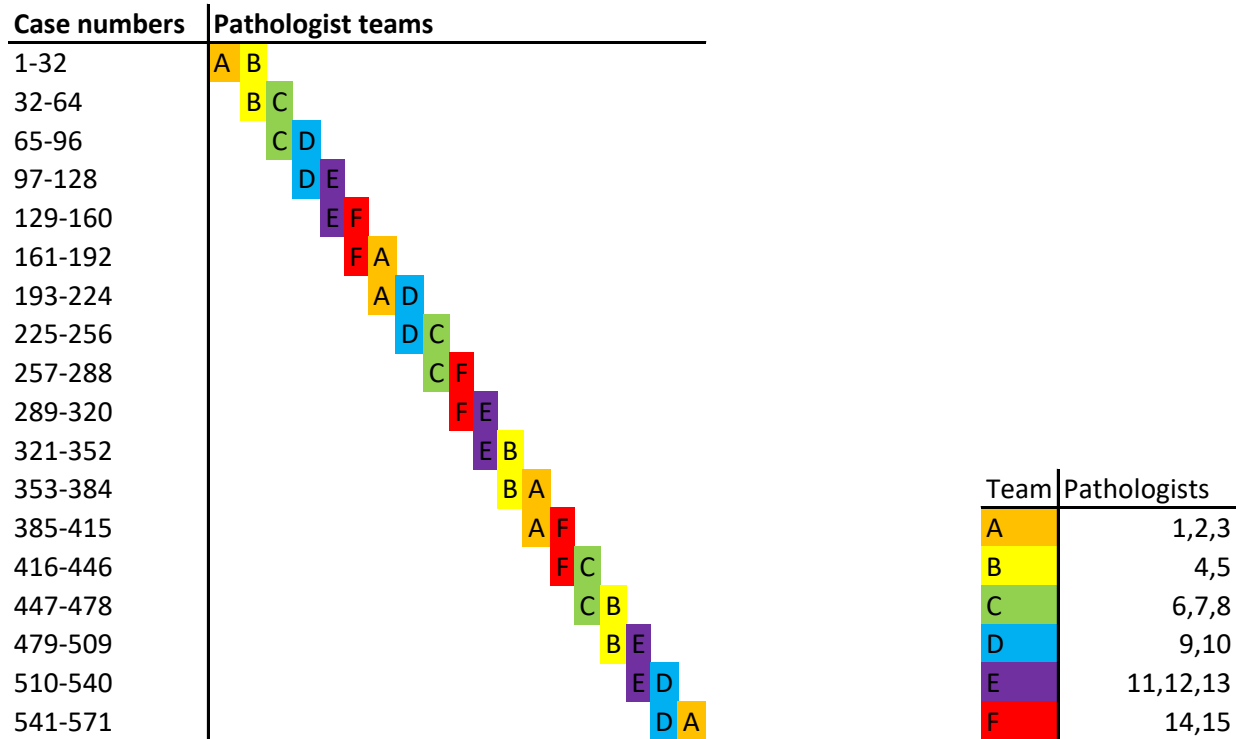
Supplementary material to:

“Deep learning detects premalignant lesions in the Fallopian tube”

Table of content:

Supplementary figure 1	page 2
Supplementary figure 2	page 3-4

Supplementary figure 1









Supplementary figure 1: The left column represents the case numbers

The teams of pathologist are represented by a letter (A-F)

The number of pathologists per group and the color coding of the groups is presented in the legend

Supplementary figure 2





Supplementary figure 2: Overview of the reference standard, resulting from the reader study.
 Each cell represents a single specimen. Each row represents a reader. Diagnoses are color coded as presented in the legend.