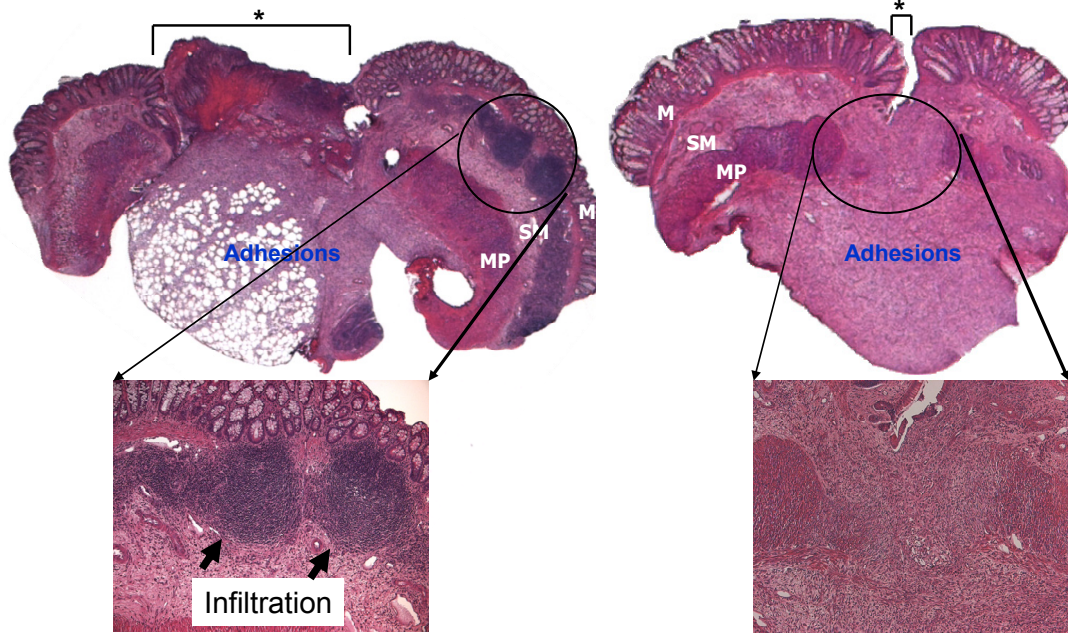


Group IV: preoperative irradiation followed by anastomosis and cecal injection of *P. aeruginosa*

Group II: anastomosis and cecal injection of *P. aeruginosa*



Supplemental Fig.S1. Histological analysis of anastomotic tissues from rats of experimental groups II and IV. M= mucosa; SM= submucosa; MP= muscularis propria; * = anastomosis.